

Case Report

## Occult Aspiration of Chicken Wishbone Lodged in the Larynx

Usama F Kamel<sup>1</sup>\* MD, FRCSEd, PGCPCE, MBBCh Dr James W Rudd<sup>2</sup> MBBS, Prof Henry Pau<sup>2</sup> MD, FRCS

<sup>1</sup>Department of Otolaryngology Head & Neck Surgery, Queen's Medical Centre Nottingham University Hospitals, Nottingham, England

<sup>2</sup>Department of Otolaryngology Head & Neck Surgery, Leicester Royal Infirmary, University Hospitals of Leicester, Leicester, England

\*Corresponding author: : Dr. Usama F Kamel, 12 Chelsea Drive, Sutton Coldfield, B74 4UG, West Midlands, England, UK,

Tel: +44 7957 302550; E mail: ukamel@hotmail.com

Received: 03-04-2015

Accepted: 03-25-2015

Published: 04-01-2015

Copyright: © 2015 Usama

### Abstract

A 22 years old man presented to emergency department with progressive shortness of breath and stridor over a three months period. He had no history of foreign body ingestion or choking. He is a well articulate athletic Down's syndrome. He had a repair for ventricular septal defect at 3 months age. Fibreoptic naso-laryngeal endoscopy showed granulation tissue on his vocal cords with foreign body appearance between the cords. CT scan of his neck and chest showed a wishbone foreign body appearance at his larynx. Tracheostomy and micro-laryngobronchoscopy were performed.

**Keywords:** Stridor; Foreign Body; Larynx; Trachea; Wishbone

### Objective

Foreign body inhalation is a life threatening airway emergency. Most cases are due to food causing asphyxiation. Occult cases are usually due to small tracheobronchial FB causing dyspnoea, recurrent chest infection and associated fever. Diagnosis require chest X ray, Flexible bronchoscopy before general anaesthetic rigid bronchoscopy to retrieve the FB [ ]. Adult impacted FB in larynx rarely passes unnoticed. The usual presentation is to emergency department following the incident. Occult cases are most commonly encountered in children [ ]. An occult foreign body aspiration in a non-emergency situation has rarely been reported in adults [ ]. We present a case of chronic chicken wishbone aspiration that presented with acute stridor due to late vocal cord swelling.

### Conclusion

Careful history and examination (endoscopic) are important to diagnose occult foreign body in the upper airway. Investigation (CT scan in this case) is essential to show the level and size of

the wishbone so further management could be planned

### Case Report

A 22 years old non smoker male with Down's syndrome, hypothyroidism, ventricular septal defect repaired at three months of age presented with a hoarse voice and biphasic stridor on exertion. He complained that he recently over the last three months became unable to fully engage in playing and coaching football. His voice has become gruffly, short of breath with noisy breathing on exercising. He had two course of antibiotic by his GP as diagnosed with laryngitis. Examination with fibreoptic nasendoscopy showed granulation tissue and swelling of the vocal cords. A CT neck was requested which showed the narrow airway and the wishbone foreign body. Figure 1&2 Tracheostomy under local anaesthetic was performed in a standard technique prior to Microlaryngobronchoscopy to secure the airway. On direct pharyngo-laryngoscopy a chicken wishbone was seen surrounded by vocal cords' granulation tissue. Figure 3 Using rigid grasping forceps endoscope, the wishbone was dislodged distally before retrieved in toto. Figure 4 The

patient made an unremarkable recovery. He was kept under observation in the intensive care unit for two days then to the general ENT ward. He had systemic steroids (Dexamethasone) for three days and Augmentin antibiotic for a week. He was discharged eight days later. He was weaned of his tracheostomy tube before discharge. The patient was reviewed a month later; he had full restoration of his original quality of voice.

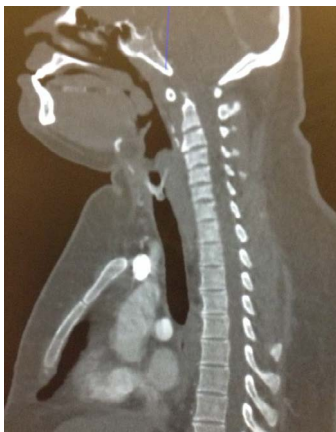

Figure 1

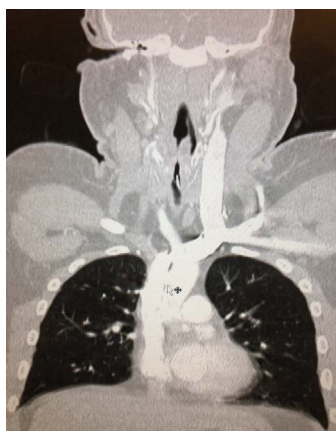


Figure 2

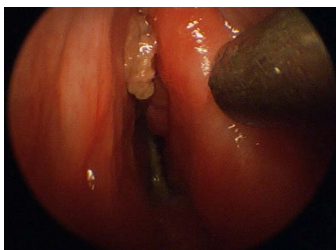

Figure 3

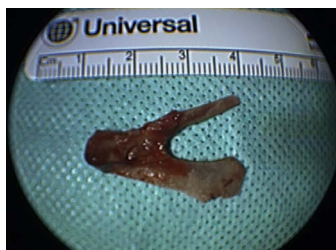

Figure 4

## Discussion

Laryngeal foreign body typically presents as an emergency requiring surgical intervention. Airway foreign bodies are more common in children than adults, boys more than girls [ ]. Other cases have been reported of foreign bodies in the larynx but few are of chronic nature. These cases commonly include children or patients with learning difficulties and/or cognitive impairment [1].

There are few cases in the literature involving chicken wishbones in adults, none that are lodged in the larynx [ ]. Asymptomatic coin lodged in the larynx has been reported [ ]. Ingested impacted wishbone in the gut was previously reported [ ]. In our case the significance was that the patient did not complain to his family doctor or attended to emergency department as an emergency when it took place. Inhaled foreign body can be a challenge for diagnosis [ ]. Different techniques were described to remove the airway foreign bodies, most notably flexible and rigid bronchoscopy [ ]. In our case, due to the airway narrowing, tracheostomy was first performed under local anaesthetic to secure the airway, followed by general anaes-

thetic through tracheostomy tube and microlaryngobronchoscopy was performed to retrieve the wishbone.

## Summary

- Occult foreign body inhalation should be considered in adults when presented with biphasic stridor, shortness of breath and cough.
- Laryngeal airway oedema and narrowing are serious consequences of foreign body inhalation
- Fibre-optic nasal endoscopy and imaging are the cornerstone to assess airway adequacy

## Grants and financial support

We had neither grants nor financial support to present this work. We have no conflict of interest to declare.

## References

1. Wolkove N, Kreisman H, Cohen C, Frank H. Occult foreign-body aspiration in adults, JAMA 1982, 248(11): 1350-1352.
2. Sahni JK, Mathur NN, Kansal Y, Rana I. Bronchial foreign body presenting as an accidental radiological finding. Int J Pediatr Otorhinolaryngol. 2002, 64(3): 229-232.
3. Ghaffarlou M, Golzari SE, Nezami N. A large asymptomatic foreign body in larynx and trachea. Quant Imaging Med Surg. 2014, 4(3): 210-211.
4. Rothmann BF, Boeckman CR. Foreign bodies in the larynx and tracheobronchial tree in children. A review of 225 cases. Ann Otol Rhinol Laryngol. 1980, 89(5.1): 434-436.
5. O'Sullivan ST, McGreal GT, Reardon CM, Hehir DJ, Kirwan WO et al. Selective endoscopy in management of ingested foreign bodies of the upper gastrointestinal tract: is it safe?. Int J Clin Pract. 1997, 51(5): 289-292.
6. Vaid L. Asymptomatic impacted foreign body of larynx. Indian J Otolaryngol Head Neck Surg. 2003, 55(4): 285-287.
7. Mondin RM, Fandino M, Carpes LF, Tang J, Ogilvie LN et al. Esophageal Wishbone Extraction: Not for the Chicken-Hearted. Ann Otol Rhinol Laryngol. 2015, 124(1): 79-82.
8. Di Marco CJ, Mauer TP, Reinhard RN. Airway foreign bodies: A diagnostic challenge. J Am Osteopath Assoc. 1991, 91(5): 481-486.
9. Rafan AL, Mehta AC. Adult airway foreign body removal. What's new?. Clin Chest Med. 2001, 22(2): 319-330.