

Research Article

A Case Series of Virtual Surgical Planning in Mandibular Reconstruction

Jon P. Ver Halen^{1*}, Anas Eid¹

¹Division of Plastic and Reconstructive Surgery, Baptist Cancer Center

²Department of Surgery, Vanderbilt-Ingram Cancer Center, Nashville, TN

*Corresponding author: Dr. Jon P. Ver Halen, Division of Plastic, Reconstructive and Hand Surgery, Baptist Cancer Center Research Faculty, Vanderbilt Ingram Cancer Center Adjunct Clinical Member, St Jude Children's Research Hospital, United States, Tel: (901)227-9820; Fax: (901) 227 9825; Email: jpverhalen@gmail.com

Received: 05-25-2015

Accepted: 07-08-2015

Published: 07-16-2015

Copyright: © 2015 Jon

Abstract

Purpose

Computer applications in head and neck surgery are rapidly emerging, and create a virtual environment for presurgical planning. The purpose of this study is to evaluate initial surgical outcomes in composite mandibular resections, with reconstructions planned utilizing virtual surgery.

Patients and Methods

This retrospective study evaluated 48 consecutive patients with an average age of 54.2 years who required mandibular reconstruction at a single center. August of 2011 and August 2014. High-resolution helical computed tomography (CT) scan data was sent on a CD to a stereolithographic design company for virtual surgery planning. A virtual surgery planning session was established, at which the resection planes of the mandible, positioning of the plate, and fibula lengths/osteotomy angles were established. The surgery was then carried out using prefabricated cutting guides and manual bending of a reconstruction plate using a prefabricated plate template.

Results

Twenty-five patients had complete virtual surgical planning, with pre-bending of mandible reconstruction plate and fabrication of mandibular and fibular bone cutting guides. For comparison, twenty-three patients did not have any virtual surgical planning performed. Use of virtual surgical planning decreased a number of surgical metrics, including: total operative time (499 versus 565 minutes, $p < 0.05$); flap ischemia time (60 versus 72.5 minutes, $p < 0.05$); fibula osteotomy time (16 versus 25 minutes, $p < 0.05$); and plate bending time (0 versus 19 minutes, $p < 0.05$). These variables were present despite increasing complexity of VSP-based procedures (4.5 versus 2 osteotomies on average, $p < 0.05$; 2 versus 1.1 bone segments on average, $p < 0.05$).

Conclusions

Virtual surgical planning has a positive impact on the reconstruction of major mandibular defects through the provision of accuracy difficult to achieve through manual placement of the graft, even in the hands of experienced surgeons.

Introduction

Microsurgical reconstruction of the head and neck was popularized in 1989 by Hidalgo, with the introduction of the free fibular flap [1]. Advantages of the free fibula graft for mandibular reconstruction include a long pedicle length; wide vessel diameter; the ability to incorporate skin, muscle, and bicortical bone components; and the ability to have multiple teams working simultaneously to shorten operating time.

Traditional microvascular reconstruction involves replacing composite structures including bone, mucosa, and soft tissue. Time and precision involves osteotomies, plate bending, and presurgical modeling. With the ability to perform these grafts, however, comes the challenge of properly recreating the mandible and placing it into the appropriate position to achieve structural, aesthetic, and functional goals [2]. Traditional techniques to translate the straight fibula bone into the curved shape of the mandible and positioning it for proper bone contact are technically demanding, with a steep learning curve [3,4].

Virtual surgical planning involves using high-resolution preoperative imaging and computer aided design software to assist in planning and carrying out these reconstructive efforts [5]. The process uses surgical simulation and 3-dimensional (3D) stereolithographic models rather than relying exclusively on intraoperative manual approximations of mandible reconstruction. This technique is thought to improve efficacy and efficiency with respect to resection, donor site planning, bone graft placement, and plate fabrication.

The purpose of this preliminary report is to review a three year experience with VSP cases for mandible reconstruction. We have compared this series to a concurrent cohort of patients without VSP. Our preliminary conclusions outline some of the advantages and disadvantages of using VSP for mandible reconstruction.

Patients and Methods

This retrospective study evaluated 48 consecutive patients with a median age of 54.2 years who required mandibular reconstruction by a single surgeon, between August 1, 2011 and July 31, 2014. All study aspects were approved by the respective institutional review boards (IRB). All procedures were performed by the senior author (JPV). All reconstructions were for primary or secondary oncologic, traumatic, or osteoradionecrosis etiologies.

For VSP patients, high-resolution helical computed tomography (CT) scan data was saved in Digital Imaging and Communications in Medicine (DICOM) format, and was then sent to

a virtual surgical planning company (Medical Modeling, Boulder, Colorado, USA) for reconstruction and planning. A virtual surgery planning session was established, at which time the resection planes of the mandible, position and contour of the mandible reconstruction plate, and fibula lengths and osteotomy angles were designed. Stereolithographic models were then fabricated, which included fibular osteotomy guides, and mandible constructs to guide custom plate bending and/or fabrication. Based on this data, a prebent titanium plate was generated, precisely matching the contours of the native jaw and interposed fibula flap. The final surgery was then carried out using prefabricated fibular cutting guides and the pre-bent reconstruction plate. During surgery, the sterilized fibula cutting guide was fixed temporarily to the *in situ* fibula bone using 10-mm monocortical screws, and a reciprocating saw blade was inserted into slots in the cutting guide to make osteotomies at the lengths and angles required to replicate the virtual plan.

For non-VSP patients, no preoperative models were used. Mandible reconstruction plates were bent intra-operatively, according to plate bending templates conformed to the native mandible prior to tumor resection. Fibular osteotomies were free-handed, based on expected construct bone segment lengths and angles. In both VSP and non-VSP cases, fibular osteotomies were performed *in situ* on the leg, prior to division of the fibula flap pedicle and start of ischemia time.

Patient charts were reviewed for patient demographics, intraoperative factors, and outcomes. Demographics were recorded, including patient age, sex, and diagnosis. Intraoperative factors were evaluated, including site of mandible resection and reconstruction, skin paddle type, number of segmental osteotomies, osteotomy and plate bending time, flap ischemia time (time from pedicle division to reanastomosis), and total operative time (time from skin incision to closure). Perioperative and long-term outcomes were assessed, including partial skin or bone flap loss, total skin or bone flap loss, and secondary skin or bone grafting. Statistical analysis compared patient demographics, intraoperative factors, and outcomes between conventional and VSP fibula free flap groups. Contingency data are presented as percentages, whereas continuous data are presented as means with standard of deviations or medians with interquartile ranges (25th to 75th percentile), when appropriate. The Fisher's exact test was used for comparison of percentages. Continuous variables did not show normal distributions on Shapiro-Wilk test; therefore, statistical analyses were performed with nonparametric tests. The Mann-Whitney *U* test was used for comparison of median values. A value of $p < 0.05$ was considered significant. Statistical software was used for analysis (IBM SPSS for Mac, Version 19.0; IBM Corp., Armonk, N.Y.).

Results

A total of 48 patients were included for analysis. The median age was 54.2 years (+/- 20.2 years). The primary diagnosis was oral squamous cell carcinoma in 27 patients; desmoid tumor in 3 patients; osteosarcoma in 4 patients; osteoradionecrosis in 6 patients; Ewing's sarcoma in 1 patient; trauma in 4 patients; and ameloblastoma in 3 patients.

Virtual surgical planning with bone fibular cutting guide and pre-bent, customized mandible reconstruction plate was performed in 25 patients, and traditional technique (i.e., no virtual surgical plan, fibula cutting guide, and pre-bent plate) was performed in 23 patients. Age was not significantly different between the two groups (52.9 versus 55.3 years, $p > 0.05$). However, all measured operative metrics were significantly different between the two groups. These included total operative time (499 versus 565 minutes, $p < 0.05$); ischemia time (60 versus 72.5 minutes, $p < 0.05$); number of osteotomies performed (4.5 versus 2 osteotomies, $p < 0.05$); number of fibula bone segments in the mandible construct (2 versus 1.1 segments, $p < 0.05$); total osteotomy time (16 versus 25 minutes, $p < 0.05$); total plate bending time (0 versus 19 minutes, $p < 0.05$); and total osteotomy and plate bending time (16 versus 50 minutes, $p < 0.05$).

With regard to postoperative adverse events, 1 patient died from sepsis; 2 fibula flaps were lost; there were 2 surgical infections; there was 1 venous thrombosis requiring re-exploration; and 4 patients had delayed healing of the fibula donor site. There was no significant difference in adverse events between the VSP and non-VSP cohorts. On average, inter-incisal opening improved in both cohorts by 0.5 cm (data not significant). Occlusion was centric in 23 of 25 VSP patients, and 21 of 23 non-VSP patients (data not significant). Patients were able to tolerate a soft or regular diet in 24 of 25 VSP patients, and 22 of 23 non-VSP patients (data not significant).

Discussion

In order for virtual surgical planning (VSP) to evolve into an accepted standard for mandibular reconstruction, it needs to be faster, cheaper, and produce better outcomes than traditional techniques. VSP has relatively recently been FDA-approved for cranioplasty applications, and full sterolithographic implants are certainly soon to follow.[6,7] Some centers are applying multiple steps to the initial VSP-guided surgery, thus potentially shortening a given patient's time course until full restoration [8].

Virtual surgical planning for mandible reconstruction has been reported by numerous authors. Nearly all studies report improvement in operative metrics, including total operating room times and ischemia times. However, these data are still controversial, as not all have found improved results.[5,9-12]

Initial studies of cost-efficacy have demonstrated cost savings associated with VSP, in spite of the additional costs associated with the process. However, many of these savings are attributed to surgeon-specific factors (e.g., preparation time for pre-operative molds), and thus are not appreciated by hospitals. Finally, postoperative outcomes are commonly reported to be at least as good as traditional techniques.

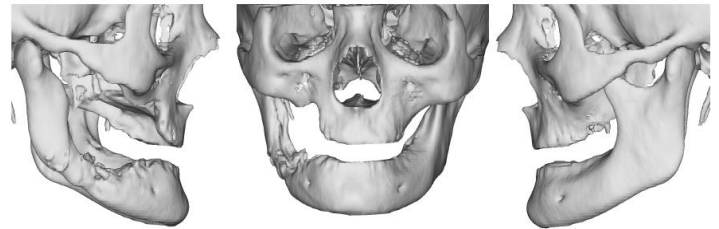


Figure 1

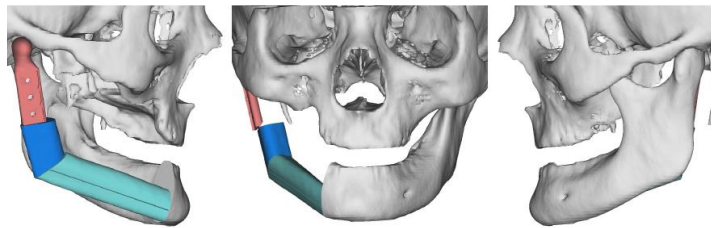


Figure 2

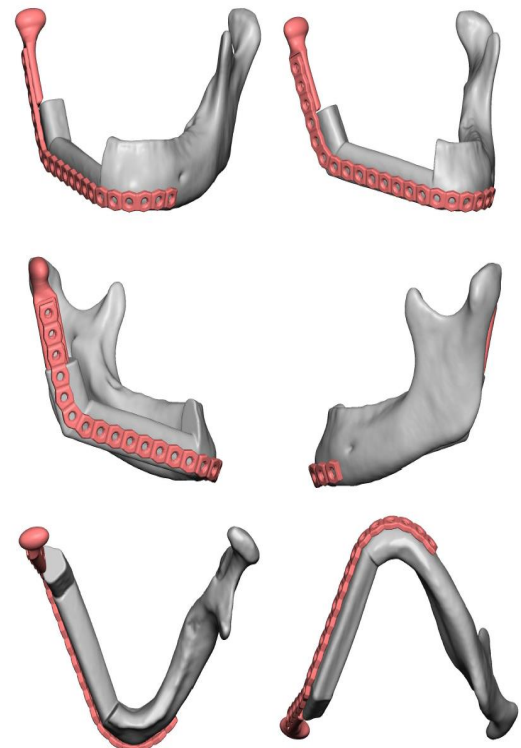


Figure 3

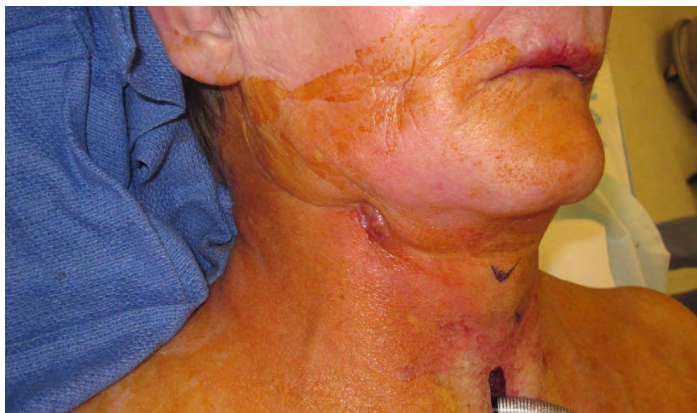

Figure 4

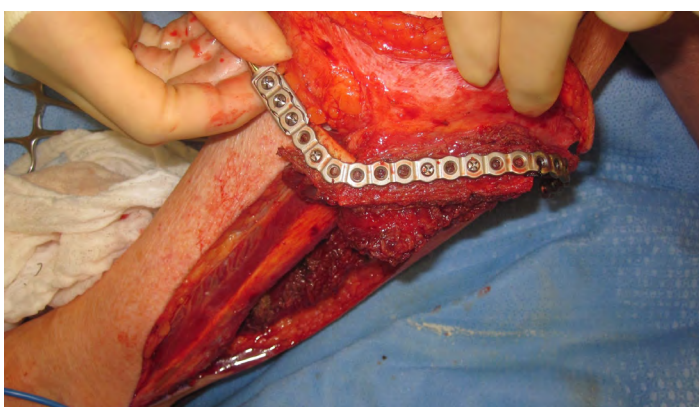


Figure 5

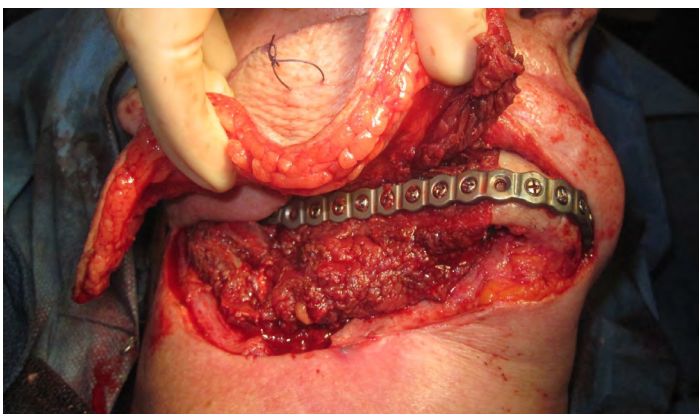


Figure 6

While VSP is helpful to surgeons and patients, until it becomes less expensive it will not be applicable to all reconstructive patients. Thus it will be necessary to properly select patients for this technique. Saad et al reported their experience with VSP in complex craniofacial reconstruction [13]. Ultimately, their inclusion criteria for use of VSP included: 1) Need for multiple simultaneous free tissue transfers; 2) Defect involving multiple parts of mandible or midface; 3) Need for multiple oste-

otomies in the reconstructive flap(s); 4) Presence of osteoradionecrosis or irradiated tissue; 5) History of high-velocity ballistic injury. This agrees with our finding of using VSP in patient with complex defects and/or compromised tissues. This includes complex articulation of the flap with native tissues; interfaces between multiple flaps; proper positioning of the vascular pedicle; and shortening ischemia time. In our study, the decision to use VSP was based on the clinical judgment of the senior author. Ultimately, those patients with an anticipated need for 2 or more fibular bone segments, or significant preoperative occlusal abnormalities were selected to undergo VSP.

Table 1. Comparison of virtual-surgical planned, versus non-VSP patients for free fibula flap mandible reconstruction on tracked surgical metrics.

	VSP cohort (n = 25 patients)	Non-VSP cohort (n = 23 patients)	P value
Age (median, years; +/- std dev)	52.9 (19.7)	55.3 (19.0)	> 0.05
Total operative time (median, minutes; +/- std dev)	499 (90.0)	565 (84.8)	< 0.05
Flap ischemia time (median, minutes; +/- std dev)	60 (33.1)	72.5 (25.3)	< 0.05
Number of fibula osteotomies (median, number; +/- std dev)	4.5 (1.8)	2 (2.1)	< 0.05
Number of fibula bone segments (median, number; +/- std dev)	2 (0.9)	1.1 (1.1)	< 0.05
Total osteotomy time (median, minutes; +/- std dev)	16 (12.2)	25 (15.9)	< 0.05
Total plate bending time (median, minutes; +/- std dev)	0 (1.2)	19 (18.9)	< 0.05
Total osteotomy time + plate bending time (median, minutes; +/- std dev)	16 (12.1)	50 (30.9)	< 0.05

In our patient series, we found significant decreases in all operative metrics. With increasing pressures on health care costs, this data will be important to support the continued use of this technology. Unlike many previous studies, we analyzed

both our VSP and non-VSP patients, for the most robust statistical analysis possible. We have a high-volume center, thus providing sufficient power to our statistical analyses. Additionally, tracking long-term surgical outcomes improves the validity of our dataset.

Ultimately, accrual of large patient cohorts, with longer follow-up will provide more evidence to support the use of VSP. For instance, while current studies track first-level operative metrics (e.g., operative time), they do not evaluate for improved synergy between ablative, reconstructive surgeons, and hospitals using VSP. If the technology is more readily available, application of VSP to other procedures (e.g., congenital cardiac surgery, breast reconstruction, orthopedic trauma) may have unforeseen benefits. Although frequently overlooked, dental rehabilitation is of utmost importance to oral cancer patients. Full utilization of VSP may allow surgeons to eliminate the time of partial or total edentulism, aiding in patients' recovery both functionally and psychologically.

Our study has a number of limitations. Our patient cohorts are not matched. More complicated cases were triaged to VSP, while simpler cases were triaged to traditional techniques. This is reflected in more osteotomies and fibula segments in VSP group, on average. Similarly, there was a higher attendant preoperative morbidity in VSP patients, in the form of previous irradiation and compromised soft tissues. In spite of this increased complexity, operative times were still significantly less in the VSP cohort. In addition, preoperative VSP sessions may last up to one hour; these times are not accounted for in our analysis. However, given the time associated with fabrication of preoperative molds (3-4 hours, on average), VSP still offers significant time savings.

Conclusions

Microsurgical craniofacial reconstruction using a computer-assisted fibula flap technique yielded significantly shorter ischemia times amidst a higher number of osteotomies compared with conventional techniques.

CPT CODING SUGGESTIONS

The authors suggest the following codes, for use during VSP planning sessions:

- CPT code 21088: Imprecision and custom preparation; facial prosthesis; or,
- CPT code 21089: Unlisted maxillofacial prosthetic procedure; or,
- CPT code 76377: #D rendering with interpretation and reporting of computed tomography, magnetic resonance imaging, ultrasound, or other tomographic

modality; requiring image post-processing on an independent workstation; or,

- HCPCS code L8048: Unspecified maxillofacial prosthesis by report, provided by a non-physician; or,
- HCPCS code L8499: Unlisted procedure for miscellaneous prosthetic service.

References

1. Hidalgo DA. Fibula free flap: A new method of mandible reconstruction. *Plast Reconstr Surg.* 1989, 84:71-79.
2. Hidalgo DA. Aesthetic improvements in free-flap mandible reconstruction. *Plast Reconstr Surg.* 1991, 88: 574-585; discussion 586-587.
3. Juergens P, Krol Z, Zeilhofer HF. Computer simulation and rapid prototyping for the reconstruction of the mandible. *J Oral Maxillofac Surg.* 2009, 67(10): 2167-2170.
4. Wang TH, Tseng CS, Hsieh CY. Using computer-aided design paper model for mandibular reconstruction: A preliminary report. *J Oral Maxillofac Surg.* 2009, 67(11): 2534-2540.
5. Roser SM, Ramachandra S, Blair H. The accuracy of virtual surgical planning in free fibula mandibular reconstruction: Comparison of planned and final results. *J Oral Maxillofac Surg.* 2010, 68(11): 2824-2832.
6. Hanson K. First 510(k) clearance for customized 3D-printed polymeric cranial implants. *MDT Magazine.* 2013.
7. Levine JP, Bae JS, Soares M. Jaw in a day: total maxillofacial reconstruction using digital technology. *Plast Reconstr Surg.* 2013, 131(6): 1386-1391.
8. Tepper O, Hirsch D, Levine J, Garfein E. The new age of three-dimensional virtual surgical planning in reconstructive plastic surgery. *Plastic Reconstruct Surg.* 2012, 130(1): 192e-194e.
9. Bell RB. Computer planning and intraoperative navigation in craniomaxillofacial surgery. *Oral Maxillofac Surg Clin North Am.* 2010, 22(1): 135-156.
10. Seruya M, Fisher M, Rodriguez ED. Computer-assisted versus conventional free fibula flap technique for craniofacial reconstruction: an outcomes comparison. *Plast Reconstr Surg.* 2013, 132(5): 1219-1228.
11. Antony A, Chen WF, Kolokythas A, Weimer KA, Cohen MN.

-
- Use of virtual surgery and stereolithography-guided osteotomy for mandibular reconstruction with the free fibula. *Plastic Reconstruct Surg.* 2011, 128(5): 1080-1084.
12. Xia JJ, Phillips CV, Gateno J. Cost-effectiveness analysis for computer-aided surgical simulation in complex cranio-maxillofacial surgery. *J Oral Maxillofac Surg.* 2006, 64(12): 1780-1784.
13. Saad A, Winters R, Wise MW. Virtual surgical planning in complex composite maxillofacial reconstruction. *Plast Reconstr Surg.* 2013, 132(3): 626-633.