

Research Article

Measurements and Three-Dimensional Computed Tomography Aspects of Styloid Apophyses in African with Black Skin

Konaté I¹, Kouassi KPB¹, Bravo-Tsri AB¹, Tanoh KE¹, Vangah K¹, N'dri K¹, Tetchi NNH², Gbazi GC², Seka AR³

¹Service de radiologie et d'Imagerie du CHU de Bouaké

²Service de radiologie et d'Imagerie du CHU de Cocody

³Service de radiologie service d'Imagerie médicale à l'Institut de Cardiologie d'Abidjan

*Corresponding author: Dr. KONATE Issa, Assistant master in medical imaging, Université Alassane Ouattara Bouaké - Côte d'Ivoire, Imagerie Médicale, 26 BP 1140 Abidjan 26, Tel: (225) 07296969 ; Email: iktata@yahoo.fr

Received: 06-23-2015

Accepted: 07-16-2015

Published: 08-25-2015

Copyright: © 2015 Konate

Abstract

Aim

Describe the styloid apophysis measurement with CT method in 3D and determine the standard length.

Patients and methods

120 patients with noclinical manifestations of abnormally elongated styloid apophysis, referred for a CT of the skull or cervical spine were examined at the CT with 3D reconstruction.

Result

Measurements of both styloid apophyses were made after helical acquisition with achievement of 3D reconstructions. The length of the styloid apophysis was obtained by measuring from the temporal base to the tip. The thickness of the base was measured and the morphology of the styloid apophysis analyzed.

The overall average length of the styloid apophysis was 25.29 mmon the right and 25.56 mm on the left with an average thickness at the base of 3.3 mm.

The variables sex, age, weight and height did not affect the length of the styloid apophysis.

Conclusion

The CT with 3D reconstruction is the ideal technique for the measurement of styloid apophyses.

Key words: styloid apophysis; length; CT

Introduction

The styloid apophysis is a bony process that emerges from the petrous portion of the temporal bone. When abnormally long, it may be responsible for irritation of the neurovascular structures with major manifestation such as the Eagle syndrome [1].

The exploration of the styloid apophysis in medical imaging has long called for conventional radiography. However, the different incidences proposed are unsatisfactory [2]. Recent, medical imaging has enabled the analysis of bone structures or calcified styloid apophyses and the musculo-ligamentous and neurovascular area [3]. In our context where access to CT is difficult, there is a shortage of information on aspects of the computed tomography of styloid apophysis.

The objective of this study is to describe the main CT aspects with 3D reconstruction of the styloid apophysis, and determine the standard length in African with black skin.

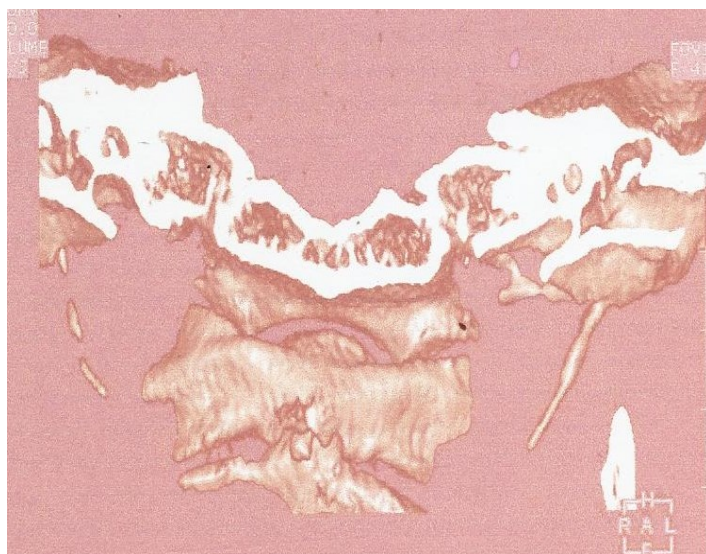


Figure 3: 3D reconstruction of the coronal volume: thin discontinuous styloid apophysis right (white arrow).




Figure 1: 3D reconstruction of the coronal volume: normal styloid apophyses.

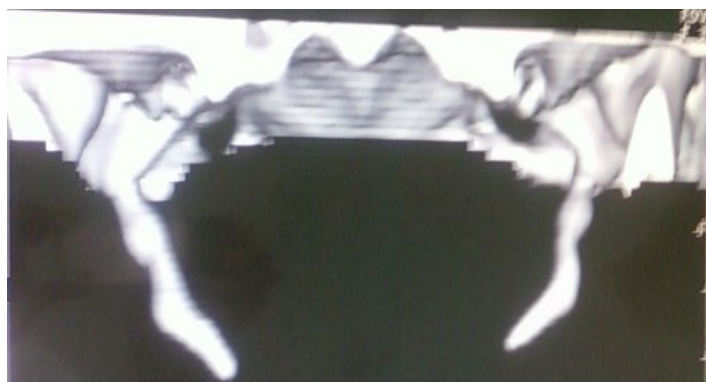

Figure 4 : 3D reconstruction of the coronal volume: stocky hooked styloid apophysis(white arrow).

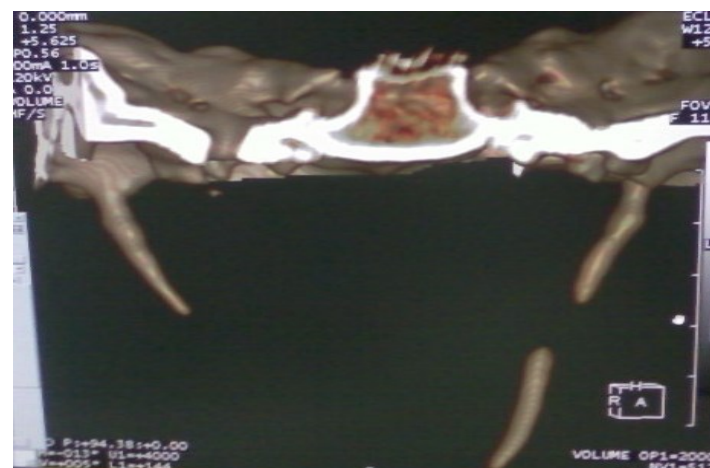

Figure 2 : 3D reconstruction of the coronal volume: discontinuous left styloid apophysis and abnormally elongated (white arrow)

Patients and methods

This is a prospective descriptive study conducted in Abidjan in the radiology department of the University Hospital of Cocody (CHU de Cocody). It covered a period of 6 months starting from September 2009 to February 2010.

It included 120 African patients with black skin referred for a computed tomography of the skull or cervical spine for various pathologies. Patients were unselected, of both sexes, displaying no debilitating disease susceptible to prevent the interrogation.

The study was conducted with the verbal consent of the patients or legal guardian for children. We excluded from the study patients with clinical manifestations of abnormally elon-

gated styloid apophysis.

They were all examined using a 16 strips HITACHI (ECLOS) scanner. The measurements of the two styloid apophyses were made after helical acquisition of axial slices of 1.25 mm thick with a pitch of 0.625.

Three-dimensional reconstructions were performed followed by the removal of other bone of adjacent structures such as the mandible, the maxilla, the zygomatic frontbone and the cervical back spine. The styloid apophysis was thus isolated, free of any disturbing superposition susceptible to distort the measurement.

The length of the styloid apophysis was obtained by measuring from its temporal base to its tip. The thickness of the base was measured and the morphology of the styloid apophysis analyzed. A second reading was made by another senior radiologist.

To collection the data, we designed a survey form that included study parameters such as identity, age, sex, weight, height and CT results. All data were analyzed using EPI INFO (6) software. Comparisons of means and proportions were made using respectively the Student test and Chi 2 test with a significance level (p) less than 0.05.

Results

Socio-demographic characteristics

Our series consisted of 120 patients, including 66 men and 54 women with a sex ratio of 1.2. The average age of patients was 45.15 ± 16.96 years (range 12 to 95 years) and the average weight was 65.57 kg with a standard deviation of 18.87 (range 34 to 151 kg). The average height of the patients was 1.66 m with a standard deviation of 0.08 (range 1.50 to 1.85 m) and body mass index (BMI) of 23.8 kg/m².

Computed Tomography Findings

Surveying 239 styloid apophyses including 120 rights and 119 lefts, we came up to the following findings:

In terms of the morphological aspects of the styloid apophyses, the aspect that we considered normal that is to say the styloid apophysis going from the base to the tip of medium thickness, represented 68% of cases or 82/120 right styloid apophyses (RSA) and 81/119 left styloid apophyses (LSA).

Apart from this aspect, three other morphological aspects were frequently encountered. These were:

- the discontinuous aspect in 18.5% of cases or 22/120 on the right and 22/119 on the left;
- the appearance of hail in 9.5% of cases or 11/120 on the right and 11/119 on the left;
- the stockyhooked aspect in 4% of cases or 5/120 on the right and 5/119 on the left.

In terms of the overall average thickness of the styloid apophysis, we found that the right styloid apophysis (RSA) had an average thickness of $3.36 \text{ mm} \pm 0.97$ with a minimum of 0.4 mm and a maximum 5.8 mm.

We also found that the left styloid apophysis (LSA) had an average thickness of $3.3 \text{ mm} \pm 1.03$ with extremes of 0.4 mm and 5.7 mm.

In terms of the overall average length of the styloid apophysis, we found that this length varied depending on the right or left side (Table I).

In terms of the correlation between the styloid apophyses and socio-demographic aspects, crosses were performed to assess:

- The correlation between the length of the styloid apophysis and sex (Table II), $p = 0.13$ was not significant, proving that the length of the styloid apophysis is not related to sex;
- The correlation between the length of the right styloid apophysis (RSA) and age, with a correlation coefficient $r = 0.00$ and $p = 0.59$;
- The correlation between the length of the left styloid apophysis (LSA) and age with a correlation coefficient $r = 0.00$ and $p = 0.69$;
- The correlation between the length of the right styloid apophysis (RSA) and the weight, with a correlation coefficient $r = 0.00$ and $p = 0.46$;
- The correlation between the length of the left styloid apophysis (LSA) and the weight, with a correlation coefficient $r = 0.00$ and $p = 0.81$;
- The correlation between the length of the right styloid apophysis (RSA) and height, with a correlation coefficient $r = 0.01$ and $p = 0.31$; and,
- The correlation between the length of the left styloid apophysis (LSA) and height, with a correlation coefficient $r = 0.01$ and $p = 0.29$.

Table 1: Overall average length of styloid apophysis (SA).

Length SA (mm)	Total Population	Men	Women
RIGHT SA	25.29 ± 7.89 [10.6 – 68.3]	25.07 ± 6.94 [12.6 – 60.2]	25.07 ± 6.94 [12.6 – 60.2]
LEFT SA	25.56 ± 9.17 [10.6 – 80.3]	26.07 ± 9.48 [10.6 – 80.3]	24.03 ± 6.38 [13.5 – 54.8]

Table 2: Correlation styloid apophysis length/sex.

Length SA (mm)	Male	Female	Total
< 25	72	72	144
[25 – 30]	38	26	64
>30	19	12	31
Total	129	110	239

Discussion

At the socio-demographic level, the study pointed out a discrete male predominance request for CT examination (54.20%) with a sex ratio of 1.2 as opposed to a concept found in the literature [4].

This discrepancy with other authors could be related to a higher purchasing capability of men in our country as opposed to women [5], knowing that the scanner is 8 to 10 times more expensive than standard radiography.

The average age of patients was 45.15 years, ranging from 12 years to 95 years. The age group of 31 to 50 years was the most affected, i.e. 44.2%. This predominance of young adults can be explained by the fact that Côte d'Ivoire is a country with a predominantly young and socially active population. This observation was made by Buraima [6] and Kouassi [7].

The average weight of the patients was 65.73 kg with a range of 35 kg and 151 kg ± 13.7; and their height varied from 1 m 50 to 1 m 85 with an average of 1m 65. At the level of the radiography, the different impacts in conventional radiography proposed for the measurement of styloid apophyses are limited by impeding overlays due to naso-sinusal partitions, the Mandibulo-facial chin hearing and the cervical spine susceptible to cause errors in the measurement [2]. In addition, an incompletely calcified styloid apophysis was hardly highlighted

on conventional clichés.

The CT filled these gaps. Indeed, the CT subject of our study, with a multi-planar reconstruction namely three-dimensional (3D) allowed a good visualization of styloid apophyses from their base to their temporal extremity [3].

The styloid apophysis had some aspects that our study highlighted namely the continuous aspects (normal), discontinuous, small and stocky hook. After the normal appearance (68%), comes the discontinuous aspect representing 44 cases or 18%. This aspect is consecutive to insufficient calcification of styloid apophysis, which appeared in 2 or 3 pieces and sometimes seemed to be detached from its temporal base.

The hail represented only 22 cases or 9%, it remained fine between 2 mm and 0.4 mm from base to summit. As far the stocky hook appearance is concerned, it was most often combined with a very thick base larger than 5 mm the standard being 3.3 mm.

Our study highlighted an average length of the RSA substantially equal to LSA that is 25.29 mm and 25.56 mm respectively with a little predominance on the left. This measure corresponds to the standard according to Buraima [6] who found 25.47 mm. These findings are consistent with the literature [3, 8]

In our series, the styloid apophyses of males (RSA = 25.07 mm and LSA = 26.07 mm) were longer than those of females (RSA= 24.56 mm and LSA = 24.03 mm).

In 31 cases or 25.83%, we found some styloid apophyses lengths above 30 mm; therefore unusually elongated but asymptomatic, the standard length being between 25 and 30 mm in anatomy textbooks [9, 10].

However, the comparison of statistical tests averages performed certified with non-significant values of p, attesting that the length of the SA is linked neither to sex nor the weight or the height no respectively to the age of patients.

These findings are consistent with that of the study of Greek Natsis in the Caucasian population [11], thus confirming the anatomic thesis of Jules [9]. That thesis asserts that the length of the styloid apophysis is acquired at birth and its calcification occurs progressively. However, our findings are not consistent with those of Mohamed conducted within an Arabic population in the region of Arabia Aseer [12] and that of Alpoz in a Turkish population. [13] These two studies [12, 13] objectify a change in length depending on the age and gender for the first and only the age for the second.

Our study helps to provide information on the actual length of the styloid apophysis showing for the first time in an African

population with black skin that its styloid apophysis dimensions do not differ from those of the Caucasian.

It also allows us to make a contribution to the promotion of the three-dimensional computed tomography as a method of exploration of the styloid apophysis, a method already considered as the "gold standard" in imagery of the styloid apophysis by some authors [14].

Conclusion

The overall average length of the styloid apophysis is 25.29 mm on the right and 25.56 mm on the left with an average thickness at the base of 3.3 mm. The variables sex, age, weight and height do not affect the length of the styloid apophysis as described in the literature. The CT with 3D reconstruction is the ideal technique for the accurate measurement of styloid apophyses.

References

1. Eagle WW. Elongated styloid process: Report of two cases. *Arch Otolaryngol.* 1937, 25(5): 584-587.
2. Chuany WC, Short JH, McKinney AM, Anker L, Knoll B, et al. Reversible left hemispheric ischemia secondary to carotid compression in Eagle syndrome: surgical and CT angiographic correlation. *Am J. neuroradiol.* 2007, 28(1): 143-145.
3. Karam C, Kaessa S. Syndrome de Eagle : apport du scanner avec reconstruction 3D. *Journal of neurodiology.* 2007, 34(5): 344-345.
4. Harma R. Stylalgia Clinical experience of 52 cases. *Acta otolaryngol.* 1966, 224:149-155.
5. Cote d'Ivoire, Enquête pilote sur le niveau de vie des ménages dans le district d'Abidjan, CIV-INS-2006-VO.1.
6. Buraïma F: Contribution à l'étude des apophyses styloïdes anormalement allongées : aspect épidémiologique, clinique et diagnostic à propos de 30 cas. Mémoire pour le Certificat d'étude spécialisé d'ORL et de CCF, Abidjan, 1995-1996.
7. Kouassi-Ndjeundo J, Tanon-Anoh MJ, Buraïma F, N'Gattia V, Yoda M, et al. Intérêt du profil oblique menton dégagé dans le diagnostic des apophyses styloïdes allongées en Côte d'Ivoire. *Rev Laryngol Otol Rhinol* 2012, 133:1-5.
8. Sokler K, Sandev S. New classification of the styloid process length--clinical application on the biological base. *Coll Antropol.* 2001, 25(2): 627-632.
9. Jules C. Os temporal. Anatomie descriptive in manuel d'anatomie descriptive du corps humain. Editions H. Fournier Paris 1825, 24-25.
10. Kaufman SM, Elzay RP, Irish EF. Styloid process variation. Radiologic and clinical study. *Arch Otolaryngol.* 1970, 91(5): 460-463.
11. Natsis K, Repousi E, Noussios G, Papatthanasiou E, Apostolidis S, et al. The styloid process in a Greek population: an anatomical study with clinical implications. *Anat Sci Int.* 2015, 90(2): 67-74
12. Mohammed AS, Naheeda, Sultan MK, Abdul W, Shahul H. Prevalence of elongated styloid process in Saudi population of Aseer region. *Eur J Dent.* 2013, 7(4): 449-454.
13. Alpoz E, Akar GC, Celik S, Govsa F, Lomcali G. Prevalence and pattern of stylohyoid chain complex patterns detected by panoramic radiographs among Turkish population. *Surg Radiol Anat.* 2014, 36(1): 39-46.
14. Nayak DR, Pujary K, Aggarwal M, Punnoose SE, Chaly VA. Role of three-dimensional computed tomography reconstruction in the management of elongated styloid process: a preliminary study. *J Laryngol Otol.* 2007, 121(4): 349-353.